

Brain Connectivity in Body Dysmorphic Disorder Compared with Controls: A Diffusion Tensor Imaging Study

Ben Buchanan^{1 5*}, Susan Rossell^{1 2 3}, Jerome Maller¹, Wei Lin Toh^{1 3}, Sarah Brennan^{1 2}, & David Castle^{3 4} As published in *Psychological Medicine* (2013), 1-9.

¹ Monash Alfred Psychiatry Research Centre, Central Clinical School, Faculty of Medicine, Nursing and Health Sciences, Monash University and The Alfred Hospital, Melbourne, Australia. ² Brain and Psychological Sciences Research Centre (BPsyC), Faculty of Life and Social Sciences, Swinburne University of Technology, Melbourne, Australia. ³ Departments of Psychiatry and Behavioural Science, The University of Melbourne, Melbourne, Australia. ⁴ Psychiatry, St Vincent's Hospital, Melbourne, Australia. ⁵ School of Psychology and Psychiatry, Monash University, Melbourne, Australia

*ben.buchanan@monash.edu

Background

Body dysmorphic disorder (BDD) is a mental disorder characterised by a preoccupation with an imagined defect in physical appearance, or if a slight abnormality is present, the concern is excessive. Individuals with BDD often engage in repetitive and ritualistic behaviours, including skin picking, camouflaging their supposed defect, and checking their appearance in the mirror. The prevalence of BDD is approximately 1.8% in community self report samples (Buhlmann et al., 2010).

The severe body image distortions that individuals with BDD experience suggest that fundamental cognitive and perceptual abnormalities are involved. Indeed, neuropsychological research has revealed a range of deficits, including:

- executive function (Hanes, 1998)
- information processing (Dunai, et al., 2009),
- verbal and non-verbal memory (Deckersbach et al., 2000),
- recognition of emotion in others, (Buhlmann, McNally, Tuschen-Caffier & Wilhelm, 2004) and
- visual processing (Feusner, et al., 2010).

Several neuroimaging studies have directly investigated structural and functional brain abnormalities in BDD. The right amygdala has been shown to have increased activation in response to visual stimuli in a functional magnetic resonance imaging (fMRI) study (Feusner, et al., 2007), while structural MRI techniques have shown that right amygdala volume correlates to symptom severity (Feusner, et al., 2009). Other abnormalities in areas related to emotion, such as the cingulate cortex suggest that there are deficits in the limbic system (Atmaca et al., 2010). The orbitofrontal cortex has been shown to be reduced in volume compared to controls using structural MRI (Atmaca, et al., 2010), and an fMRI study found hyperactive activation in the same area (Feusner et al., 2010). Figure 1 shows brain regions that have been implicated in past neuroimaging studies.

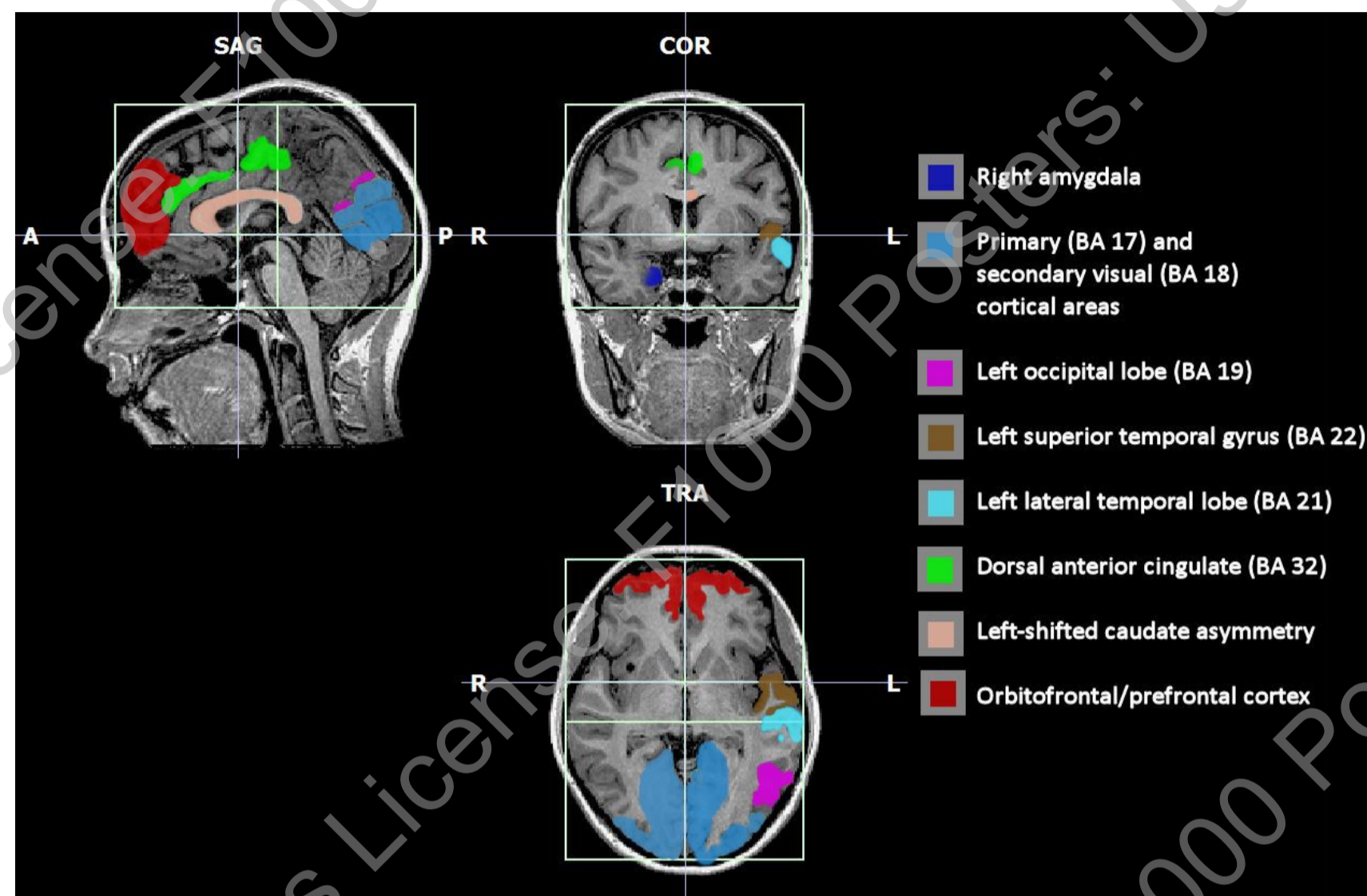


Figure 1. Implicated brain regions in body dysmorphic disorder from previous neuroimaging research

From (Buchanan, Rossell, & Castle, 2011)

Aim

Past studies have investigated the brain's grey matter areas, so this study sought to investigate white matter pathways in BDD using diffusion tensor imaging (DTI). While the brain's grey matter is involved with specific cognitive functions, white matter is primarily composed of neural tracts that allow different parts of the brain to communicate. Given that individuals with BDD have deficits in tasks that require communications between brain areas, it was hypothesised that white matter connectivity in the brain would be reduced compared to controls.

Method

Twenty participants with BDD and 20 healthy controls matched on age, sex and handedness underwent DTI using a Siemens 3T scanner. The BDD participants were recruited from the St Vincent's Hospital Body Image clinic in Melbourne, Australia. BDD patients were excluded if they had a past or current psychotic disorder, obsessive compulsive disorder, bulimia nervosa, anorexia nervosa, alcohol or substance abuse history, or other major disturbance. Fractional anisotropy (FA), a measure of water-diffusion within a voxel which represents white matter connectivity, was compared between groups on a voxel-by-voxel basis across the brain using Tract Based Spatial Statistics within FSL software (Smith et al., 2004; www.fmrib.ox.ac.uk/fsl).

Results

Results showed that, compared with healthy controls, BDD patients demonstrated significantly lower ($p < .05$) FA in most major white matter tracts throughout the brain, including the superior longitudinal fasciculus, fronto-occipital fasciculus and corpus callosum. Lower FA levels were accounted for by increased radial diffusivity as characterised by eigenvalue 2 and 3. No areas of increased FA were found in BDD. Figure 2 illustrates the widespread nature of reduced FA in the BDD sample.

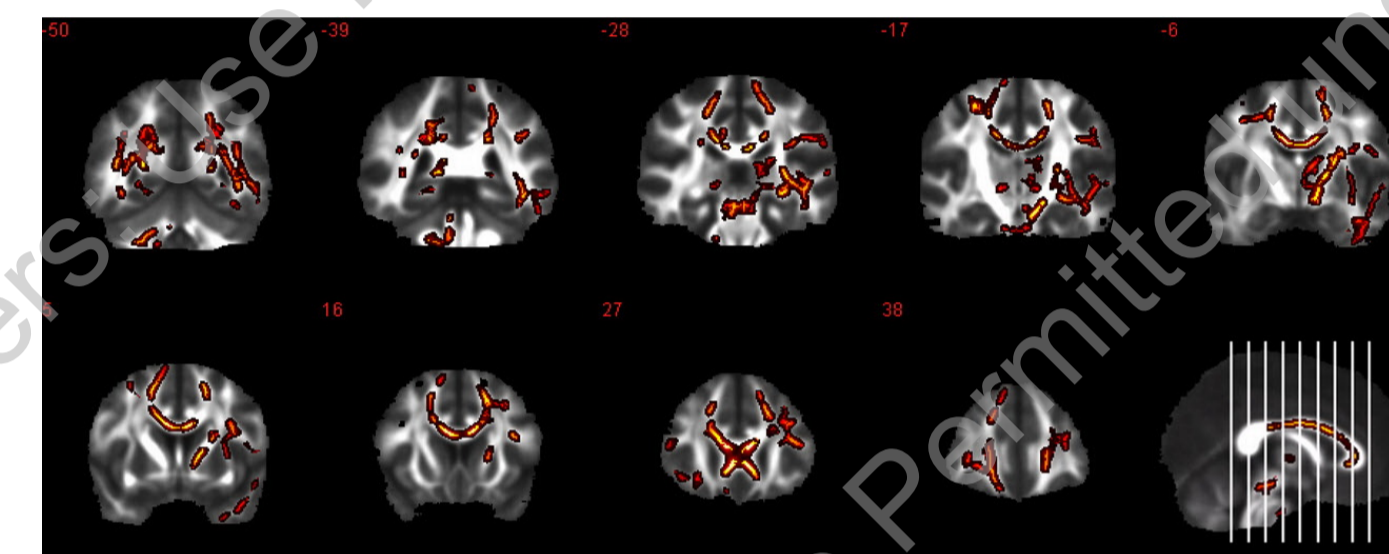


Figure 2. Mean reductions in fractional anisotropy in BDD group compared to control group

Conclusion

This study provided the first evidence of compromised white matter integrity within BDD patients. The results suggests that there are widespread inefficient connections between areas of the brain, and provides a neurobiological explanation for past studies which showed cognitive deficits and emotional dysregulation in BDD. These difficulties may be a result of compromised neural integration where the cognitive process relies heavily on connections between localised areas involved in inhibitory, parallel, or complementary cognitive processing. This data may also give light to possible treatments for BDD. Evidence that mental training like meditation (Tang et al., 2010) can increase FA in healthy individuals suggest these strategies may help within clinical populations. Future research could investigate whether reduced white matter integrity is a predisposing factor in development of BDD.

References

- Atmaca, M., Bingol, I., Aydin, A., Yildirim, H., Okur, I., Yildirim, M., et al. (2010). Brain morphology of patients with body dysmorphic disorder. *Journal of Affective Disorders*, 123(1-3), 258-263.
- Buchanan, B. G., Rossell, S. L., & Castle, D. J. (2011). Body dysmorphic disorder: a review of nosology, cognition and neurobiology. *Neuropsychiatry*, 1(1), 71-80.
- Buhlmann, (2010). Updates on the prevalence of body dysmorphic disorder: A population-based survey. *Psychiatry Research*, 178(1), 171-175.
- Buhlmann, U., McNally, R. J., Etoiff, N. L., Tuschen-Caffier, B., & Wilhelm, S. (2004). Emotion recognition deficits in body dysmorphic disorder. *Journal of Psychiatric Research*, 38, 201-206.
- Hanes, K. R. (1998). Neuropsychological performance in body dysmorphic disorder. *Journal of the International Neuropsychological Society*, 4(2), 167-171.
- Deckersbach, T., Savage, C. R., Phillips, K., Wilhelm, S., Buhlmann, U., Rauch, S. L., et al. (2000). Characteristics of memory dysfunction in body dysmorphic disorder. *Journal of the International Neuropsychological Society*, 6, 673-681.
- Dunai, J., Labuschagne, I., Castle, D., Kyrios, M., & Rossell, S. (2009). Executive function in body dysmorphic disorder. *Psychological Medicine*, 40(9), 1541-1548.
- Feusner, J., Moller, H., Altstein, L., Suger, C., Bookheimer, S., Woon, J., et al. (2010). Inverted face processing in body dysmorphic disorder. *Journal of Psychiatric Research*, 44(15), 1088-1094.
- Feusner, J., Townsend, J., Bystritsky, A., McKinley, M., Moller, H., Bookheimer, S., et al. (2009). Regional brain volumes and symptom severity in body dysmorphic disorder. *Psychiatry Research: Neuroimaging*, 172(2), 161-167.
- Tang, Y. Y., Lu, Q., Geng, X., Stein, E. A., Yang, Y., & Posner, M. I. (2010). Short-term meditation induces white matter changes in the anterior cingulate. *Proceedings of the National Academy of Sciences*, 107(35), 15649.